
IMAGES

Cranial nerve involvement in multiple myeloma

ALICIA FRAGA¹, ALBERT ARMISEN², EVA COMA²

¹Servicio de Medicina Interna. Hospital Universitario de Bellvitge, Barcelona, Spain. ²USAC. Institut Català d'Oncologia. Hospital Duran y Reynals. Barcelona, Spain.

Multiple myeloma is a proliferation of plasma cells that infiltrate various organs. The most common symptoms are attributable to bone and renal infiltration. In bone, specific treatment can induce a fusion of lesions and generate larger sized lesions. If these do not cause specific symptoms, no treatment is required.

We report the case of a male patient aged 61 years with multiple myeloma who consulted the emergency department because of the appear-

ance of some "holes" in the skull. A month before he had received the first cycle of specific treatment. Physical examination showed no focal neurologic deficits, and 2 solutions of continuity measuring 3x2 cm. were palpable. Plain radiography showed typical "salt and pepper" lesions of larger size than those palpated. The patient was discharged after explanation of the warning signs and advice on using local cranial protection.

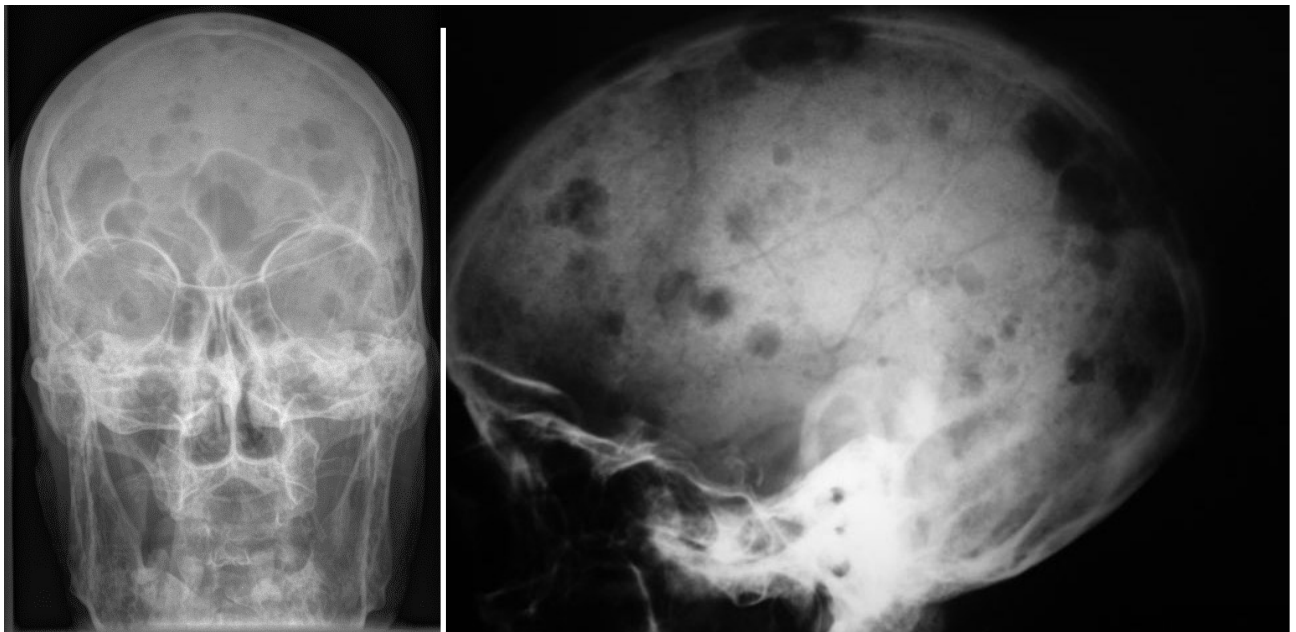


Figure 1. Plain cranial radiograph (anteroposterior, left; lateral, right) of a patient with multiple myeloma showing typical "salt and pepper" lesions.

CORRESPONDENCE: Dra. E. Coma. Institut Català d'Oncologia. Hospital Duran y Reynals. USAC. Avda. Castelldefels, s/n. 08027 L'Hospitalet de Llobregat. Barcelona, Spain. E-mail: ecoma@iconcologia.net

RECEIVED: 25-9-2008. **ACCEPTED:** 1-10-2008.

CONFLICT OF INTEREST: None.