

Value of ultrasound imaging of the lower limbs for the diagnosis of deep vein thrombosis in an emergency department

RICARDO CAMPO LINARES, JUAN SANZ CORTÉS, JOSÉ MANUEL MORALES CANO, TERESA GÓMEZ SAN ROMÁN

Servicio de Radiología. Hospital Santa Barbara. Puertollano. Ciudad Real, Spain.

CORRESPONDENCE:

Ricardo Campo Linares
C/ Malagón, s/n
13500 Puertollano
Ciudad Real, Spain.
E-mail: rcampol@yahoo.es

RECEIVED:

5-11-2008

ACCEPTED:

17-2-2009

CONFLICT OF INTEREST:

None

Objectives: 1) To describe the characteristics of patients with these symptoms. 2) To assess agreement between compression ultrasonography performed in the ED and Doppler ultrasound imaging in radiology. 3) To assess the efficacy of a diagnostic algorithm that includes ultrasound imaging, clinical characteristics, and laboratory findings.

Methods: Descriptive study of consecutive patients attending the ED complaining of symptoms suggestive of DVT. We applied a diagnostic algorithm requiring physical examination, D-dimer assessment, pretest probability (Wells score), and ED compression ultrasonography.

Results: Thirty-seven patients were included; 48.65% were men. Pretest probability according to the Wells score was low for 9 patients (24.3%; 95% confidence interval [CI], 9.1%-39.5%), moderate for 10 (27.0%; 95% CI, 11.4%-42.7%), and high for 18 (48.6%; 95% CI, 31.2%-66.1%). D-dimer level was not significantly associated with the findings of compression ultrasonography. The κ index for agreement between compression ultrasonography and the gold standard (Doppler ultrasound in the radiology department) was 1. Sensitivity was 100% (95% CI, 96.1%-100%), specificity 91.7% (95% CI, 71.9%-100%), positive predictive value 92.9% (95% CI, 75.8%-100%), and negative predictive value 100% (95% CI, 95.4%-100%).

Conclusions: The algorithm tested appears to be valid for evaluating patients who may have DVT. There is a high level of agreement between compression ultrasonography of the lower extremities in the ED and ultrasound findings reported by the radiology department. [Emergencias 2009;21:177-182]

Key words: Emergency health services. Ultrasonography. Deep vein thrombosis.

Introduction

Deep vein thrombosis (DVT) of the lower limbs is the third most frequent form of cardiovascular disease, surpassed only by ischemic cardiopathy and cerebrovascular disease¹. Its incidence, estimated at 84-180 cases/100.000 inhabitants/year, increases proportionately with age to 300 cases/100.000 inhabitants/year in people older than 80 years². Its high morbidity (responsible for 90% of acute pulmonary embolism³), the nonspecific semiological diagnosis⁴ and the existence of accessible and effective treatment have led to the development of techniques and models for diagnostic confirmation with a double objective: security of diagnosis and early treatment. Ultrasound (US)

imaging of the lower limbs has shown its usefulness in the diagnosis of DVT with a sensitivity and specificity greater than 97% in the proximal area. However, for the calf area, sensitivity is around 73%, and there are a large number of incomplete studies^{5,6}. Problems identified in leg US include the fact that it is a delicate procedure, it is time-consuming, risky and does not ensure the diagnosis. A blood clot not detected in this area can migrate to proximal territory (20%), so US follow up in 5-7 days is recommended in patients at medium to high risk^{7,8}. Suspicion of a positive diagnosis should be graduated using a scale designed for this purpose (such as the Wells index) and algorithms should be used for the diagnosis, including clinical probability, D-dimer and Doppler or compression

ultrasound. US performed at the bedside is a great help in many situations, including venous thrombosis of the lower limbs, saving time for the physician and the nurse and decreasing decision-making time by more than 2 hours^{9,10}. In recent years, this possibility has led to US being performed in the emergency department (ED) by emergency physicians. Since US was previously performed by radiology department specialists, often not available around the clock, there have been numerous studies comparing US performed by ED and radiology departments⁵.

The aim of this study was to assess the ability of an ED physician to perform compression / Doppler US in the diagnosis of DVT, and integration into a decision-making algorithm together with a Wells clinical scale¹¹ and laboratory data (D dimer).

Method

This was a diagnostic concordance study performed in the ED and radiology department of a regional hospital in an urban area. Doppler-US findings of the Radiology department were taken as the gold standard. From April 2007 to December 2007, we included all consecutive ED patients with signs or symptoms suggesting DVT. We excluded those with previous DVT in the same limb or who had undergone US with known results.

Compression ultrasonography was performed by a physician specialist in family and community medicine attached to the emergency department, with US training and 5 years regular practice as well as lower-limb Doppler US training at a recent 4h theoretical workshop. US imaging was conducted with Toshiba Ecocce TM ultrasound equipment with a 7 MHz linear probe and a 3.5 mHz convex lens (examination of the inferior cava and iliac veins). We performed statistical analysis of the data using Stata 9.0, and the analysis of contingency tables was performed with Epidat 3.1. The variables are presented as means and standard deviation and proportions with 95% confidence intervals. Chi-square test was used to compare quantitative variables, and Student t test for qualitative variables. Kappa index was used to calculate concordance (0.81 to 1: very good, 0.61 to 0.80: good; 0.41 to 0.60: moderate, 0.2 to 0.40: low, < 0.20 poor).

In ED compression ultrasound, the diagnosis of DVT was based on the inability to compress the vein (Figures 1 and 2), but other findings were assessed, such as vein enlargement, interior echogenic material, absence of flow and no increase in

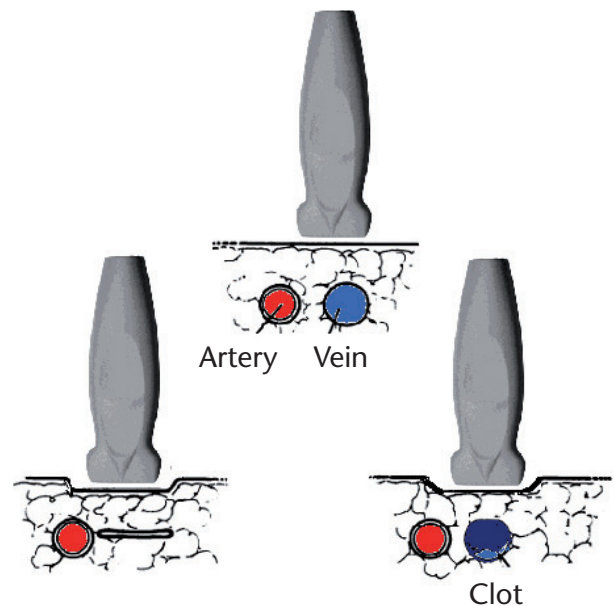


Figure 1. Outline of the compression maneuver.

the flow after “increment maneuvers” (although the latter as complementary to the absence of compression).

The symptomatic limb was systematically examined from the groin to the popliteal junction in prone and supine positions (Figure 3). Before the US procedure, we recorded data from the physical examination, personal history and anamnesis, and clinical probability was assessed with the Wells predictive model¹¹ (Table 1). Qualitative D-dimer was later determined in the laboratory by a latex aggregation technique.

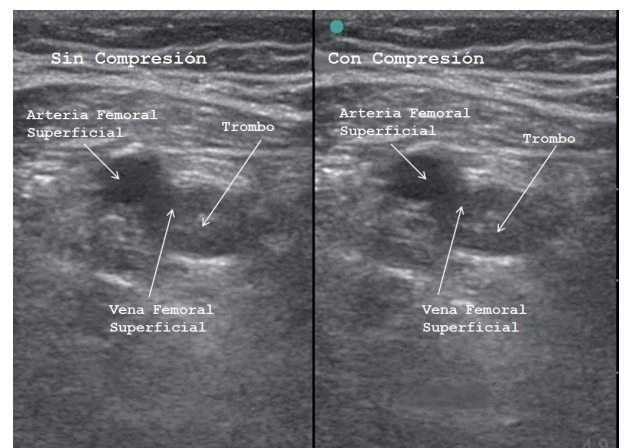


Figure 2. Ultrasound image of deep vein thrombosis. The femoral artery and vein can be seen with a thrombus (echogenic image inside the vein lumen), without (left) and with (right) compression, with no modification of the image.

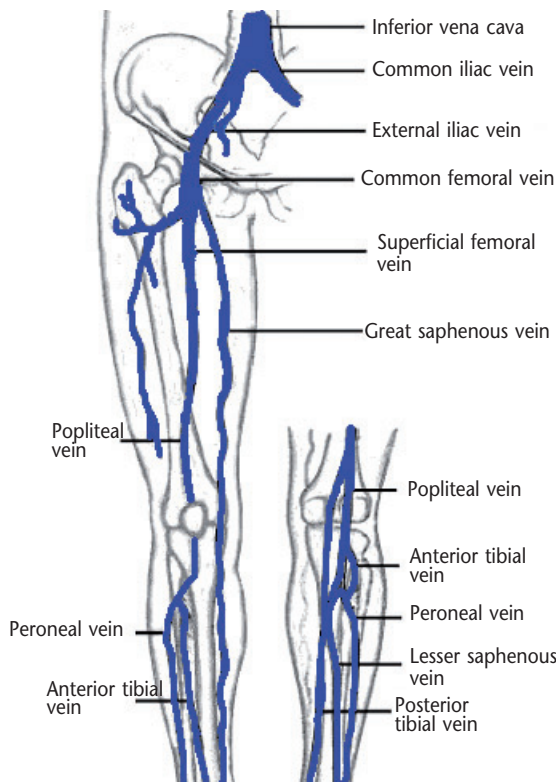


Figure 3. Deep venous system of lower limb.

Patients with positive or indeterminate US findings were admitted to the internal medicine department and treated with anticoagulants, firstly low-molecular-weight heparin and then oral anti-coagulants.

During the admission process, venous Doppler-US was performed in the radiology department. Patients with negative US, medium-high clinical probability and positive D dimer were discharged without treatment, with primary care follow-up and outpatient Doppler US in the radiology department within a week. Patients with low clinical probability were discharged, with primary care follow-up. The definitive diagnosis of DVT was made by the radiology department.

Table 1. Wells Index

Criteria	Score
Active neoplasia	1
Paralysis or recent plaster cast immobilization	1
Recent major surgery or immobilization	1
Localized pain along distribution of deep venous system	1
Swelling of the limb	1
Calf swelling > 3 cm (measured 10 cm below tibial tuberosity)	1
Pitting edema (confined to symptomatic leg)	1
Collateral superficial veins (non-varicose)	1
Alternative diagnosis at least as likely	-2
High probability: > 2 points. Medium probability: 1-2 points. Low probability: < 1 point.	

Three months later, we performed a chart review of the patients to detect any new episodes of venous thromboembolism.

Results

The study included 37 patients, one being excluded due to suspected lung thromboembolism and another due to previous DVT in the same limb. Demographic data: 48.6% of cases were men, 52.4% were women. Mean age of the men was 62.7 years (± 17.42) and of the women it was 65.36 years (± 15.42), ($p = NS$).

Regarding risk factors, the following were not present in any case: pelvic or lower limb trauma, surgery, heart failure, deficiency of protein C, S and antithrombin III, antiphospholipid syndrome and use of oral contraceptives. Other risk factors are shown in Table 2. Data from the physical examination are shown in Table 3.

Patients were classified according to categories using the Wells predictive model which classifies patients in three groups. This study pooled the medium and high risk groups. In the category of low risk there were 9 patients (24.3%, 95% CI 9.1-39.5), and 28 patients in the medium-high risk group (75.7%, 95% CI 60.5-90.8).

There was no statistically significant association between D-dimer performed in isolation and the diagnosis of thrombosis by the radiology department. Only one patient with negative D-dimer presented DVT. A Kappa index of 1 was found for the concordance between ED and radiology department diagnoses of DVT; after 1 week follow-up, this was 0.88.

Using the Doppler-US findings of the radiology department as the gold standard, ED-performed compression US diagnoses of DVT showed a sensitivity of 100% (96.1-100), specificity of 91.7% (71.9-100), positive predictive value of 92.9% (75.8-100) and a negative predictive value of 100% (95.4-100).

The result of the use of the diagnostic algorithm (Wells model, D-dimer and ED ultrasound)

Table 2. Risk factors by sex

	Men % (CI95%)	Women % (CI95%)
Immobilization	27.8 (9.7-53.5)	5.3 (0.1-26.0)
Previous thrombosis	11.1 (1.4-34.7)	15.8 (3.4-39.6)
Malignancy	33.3 (13.3-59.0)	15.8 (3.4-39.6)
Pregnancy	-	05.6 (0.1-26.0)
Age > 75 years	11.1 (1.4-34.7)	21.0 (6.0-45.6)

No statistically significant differences.

Table 3. Physical examination

	DVT % (CI95%)	No DVT % (CI95%)
Homans sign*	61.5 (31.6-86.1)	21.7 (7.5-43.7)
Malleolar perimeter > 3 cm*	57.1 (28.8-82.3)	8.7 (1.1-28.0)
Temperature	64.3 (35.1-87.2)	30.4 (13.2-52.9)
Compression pain	64.3 (35.1-87.2)	56.5 (34.1-78.9)
Colour	50 (23.0-78.0)	17.4 (4.9-38.8)
Collateral circulation	28.6 (8.4-58.1)	8.7 (1.1-28.0)
Edema	85.7 (57.2-98.2)	56.5 (34.1-76.9)
Cord-like varicose vein	21.4 (4.7-50.8)	4.3 (0.1-21.9)

*Statistically significant difference.

used as a gold standard diagnosis of DVT by the radiology service, including 1 week follow-up, was as follows: Odds ratio of presenting DVT in patients classified as such by the algorithm was 273 (12.4-12080).

The sensitivity of the algorithm was 92.9% (75.8-100), specificity 95.4% (84.5-100), positive predictive value 92.9% (75.8-100), and negative predictive value was 95.5% (84.5-100).

At 3 months after the initial ED US, only one patient developed DVT, and this was infrapopliteal. It was diagnosed in the radiology department using venous Doppler ultrasound, described as "isolated thrombus in the posterior tibia vein" and referred to the patient's primary care physician who decided against anticoagulation.

One patient with high clinical probability of vein thrombosis, positive D-dimer and clinical data of cellulitis but a negative ED US was admitted. For intravenous antibiotic treatment, prior US by the radiology department indicated DVT on the basis of indirect data (slow flow) and, given the doubt, US was repeated 24 h later. Finally, the patient was considered negative for DVT.

Although not part of the study, US assessment of the deep vein system of the calf was attempted in almost all patients. ED US in only one patient was interpreted as infrapopliteal DVT, but the radiology department findings indicated superficial venous thrombosis (thrombotic communications between varicose and superficial venous system). This finding was not taken into account.

Discussion

With respect to ED patients attending for lower limb pain and swelling, compression US performed by experienced ED physicians may be considered a reliable technique which accelerates the diagnosis, often laborious, of DVT.

The isolated use of D-dimer was not sufficient to exclude the diagnosis of DVT. In this study we

found only one patient with DVT in the negative D-dimer group, and there was no relationship between the diagnosis of DVT and the D-dimer result, so this test should only be done when clinical probability is low, with no further studies if D-dimer is negative (probability of DVT <1%).

It is necessary to integrate the results of compression US into the algorithm of clinical probability, as proposed by Frazee and Snoey¹². Patients with medium-high probability and negative US should be reviewed within a period of 5-7 days. Of the patients studied, all confirmed cases of DVT had medium or high pre-test probability according to the Wells index. None of the patients with medium or high probability and negative compression US underwent Doppler ultrasound in the radiology department after one week.

These results suggest that an algorithm including clinical probability by Wells-type indexes, D-dimer (qualitative method, life-type) together with ED compression US may be efficient. Patients with low clinical probability and negative D-dimer could be discharged without further testing. Patients with low clinical probability and positive D-dimer should undergo Doppler compression US in ED, and the negative cases could be discharged for outpatient monitoring in primary care. Patients with medium-high probability should receive Doppler compression US in the ED; if negative, US review should be performed within a week to minimize the risk of a popliteal thrombus progressing to proximal territory.

Although not very large, the sample size was sufficient to obtain statistically significant results on the use of the diagnostic algorithm; more extensive studies should therefore allow us to draw even more significant conclusions.

In reviewing the literature on this, we found that in the study by Frazee et al.¹², 12 of the 76 patients undergoing US studies were indeterminate (2 had DVT), with a consequent decrease in specificity (73.9%) and negative predictive value (53.3%), since they considered the indeterminate cases as DVT. All their ED studies were accompanied by a Doppler US performed by the radiology department. In our work, only the positive ED studies were followed by US imaging in the radiology department. We found no indeterminate US in our study, with a consequent increase in specificity. This may be explained by the fact that, in difficult territory, colour Doppler and Doppler zoom maneuvers were used, which are sometimes helpful in evaluating the presence of flow and allow differentiation between artery and vein (although this is not essential).

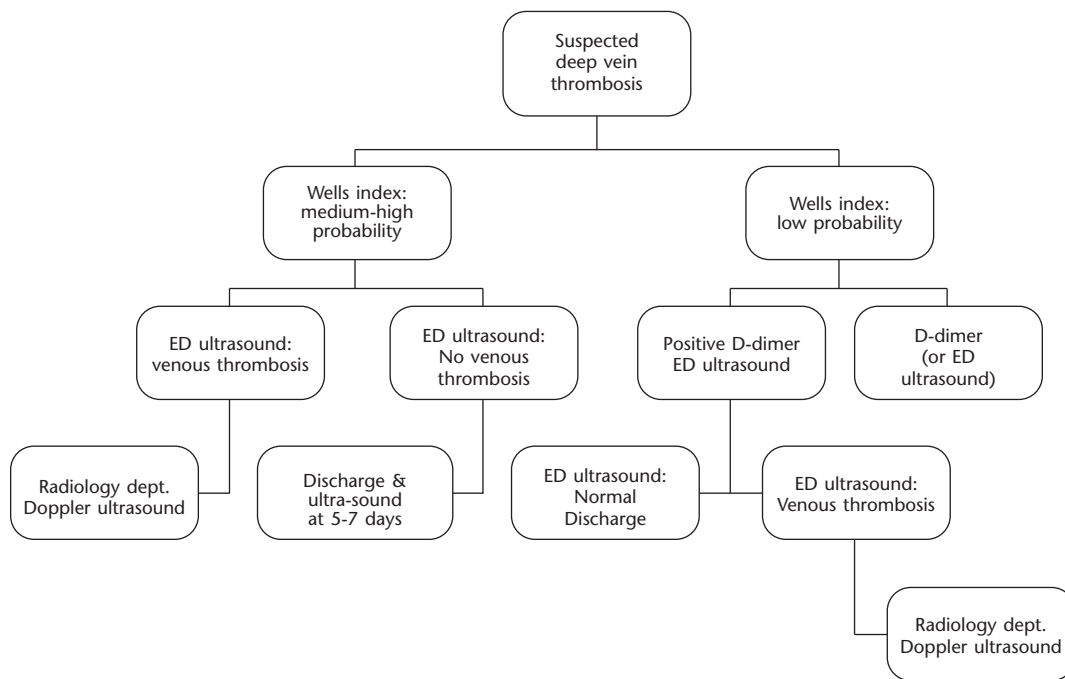


Figure 4. Diagnostic algorithm. ED: Hospital Emergency Department.

Blaivas et al.⁹ obtained a concordance index with their vascular laboratory findings similar to ours (Kappa 0.9), which demonstrated that adding colour Doppler helps to differentiate the vessels and decreases the number of studies deemed indeterminate. The results of our work are similar to those of Jolly and Massarin¹³ who obtained a sensitivity of 100% and a specificity of 75% with two false positives (old DVT).

This study is a reflection of the current international trend to increased use of ultrasound in ED. Ultrasound allows us to enhance our autonomy, accuracy and safety in handling venous thromboembolism. In addition, it is efficient in that it does not include new tests, but rather reorders the tests used routinely, without increasing costs.

References

- 1 Pearson SD, Polak JL, Cartwright S, McCabe-Hassan S, Lee TH, Goldhaber SZ. A critical pathway to evaluate suspected deep vein thrombosis. *Arch Intern Med* 1995;155:1773-8.
- 2 Khan SR. The clinical diagnosis of deep venous thrombosis: integrating

- incidente, risk factors, and symptoms and signs. *Arch Intern Med* 1998;158:2315-23.
- 3 Havig O. Deep vein thrombosis and pulmonary embolism. An autopsy study with multiple regression analysis of possible risk factors. *Acta Chir Scand Suppl* 1977;478:1.
- 4 Birdwell BC, Raskob GE, Whitsett TL, Durica SS, Comp PC, George JN. The clinical validity of normal compression ultrasonography in outpatients suspected of having deep venous thrombosis. *Ann Intern Med* 1998;128:1.
- 5 Appelman PT, De Jong TE, Lampmann LE. Deep venous thrombosis of the leg: US findings. *Radiology* 1987;163:743-6.
- 6 Cronan JJ, Dorfman GS, Grusmark J. Lower-extremity deep venous thrombosis: further experience with and refinements of US assessment. *Radiology* 1988;168:101-7.
- 7 McIlrath ST, Blaivas M, Lyon M. Patient follow-up after negative lower extremity bedside ultrasound for deep venous thrombosis in the ED. *Am J Emerg Med* 2006;24:325-8.
- 8 O'Shaughnessy AM, Fitzgerald DE. The value of duplex ultrasound in the follow-up of acute calf vein thrombosis. *Int Angiol* 1997;16:142-6.
- 9 Blaivas M, Lambert M, Harwood R, Wood JP, Knocki J. Lower-extremity Doppler for deep venous thrombosis—can emergency physicians be accurate and fast? *Acad Emerg Med* 200;7:120-6.
- 10 Theodoro D, Blaivas M, Duggal S, Snyder G, Lucas M. Real-time B-mode ultrasound in the ED saves time in the diagnosis of deep vein thrombosis (DVT). *Am J Emerg Med* 2004;22:197-200.
- 11 Wells PS, Anderson DR, Bormanis J, Guy F, Mitchell M, Gray L, et al. Value of assessment of pretest probability of deep-vein thrombosis in clinical management. *Lancet* 1997;350:1795-8.
- 12 Frazee BW, Snoey ER, Levitt A. Emergency department compression ultrasound to diagnose proximal deep vein thrombosis. *J Emerg Med* 2001;20:107-12.
- 13 Jolly TB, Massarin E, Pigman C. Color Doppler ultrasonography by emergency physicians for the diagnosis of acute deep venous thrombosis. *Acad Emerg Med* 1997;4:129-32.

Valor de la ecografía de extremidades inferiores para el diagnóstico de la trombosis venosa profunda en un servicio de urgencias

Campo Linares R, Sanz Cortés J, Morales Cano JM, Gómez San Román T

Objetivos: Describir las características de los pacientes con trombosis venosa profunda (VTP); valorar la concordancia entre la ecografía de compresión realizada en el servicio de urgencias hospitalario (SUH) y la realizada en el de radiología; y valorar la efectividad de un algoritmo que incluya la ecografía, características clínicas y pruebas de laboratorio.

Método: Estudio descriptivo de pacientes consecutivos con clínica sugerente de TVP que consultaron en nuestro SUH. Los pacientes se sometieron a un algoritmo diagnóstico que incluía exploración física, dímero D, probabilidad clínica a través del índice de Wells y ecografía de compresión en urgencias.

Resultados: Treinta y siete pacientes se incluyeron en el estudio. El 48,6% eran hombres. Nueve pacientes (24,3%) tenían baja probabilidad de TVP según el índice Wells, 10 (27%) probabilidad media y 18 (48,6%) alta probabilidad. El dímero D no obtuvo relación estadísticamente significativa con el resultado de la ecografía de compresión. El índice Kappa de la ecografía de compresión respecto al patrón oro (ecografía-Doppler venoso realizada en radiología) fue 1. La sensibilidad fue del 100%, la especificidad del 91,7%, el valor predictivo de 92,86% (75,8-100) y el valor predictivo negativo del 100%.

Conclusiones: Nuestro algoritmo puede ser válido en la valoración de pacientes con sospecha de TVP. La ecografía de compresión en extremidades inferiores por parte de médicos de urgencias tiene una concordancia elevada con la realizada en radiología. [Emergencias 2009;21:177-182]

Palabras clave: Urgencias. Ecografía. Trombosis venosa profunda.