



Clinical Note

Sheathed goring. A not obvious but devastating injury

D. Martínez-Ramos, C. Villegas-Cánovas, I. Rivadulla-Serrano, J. L. Salvador-Sanchís

DEPARTMENT OF GENERAL AND GASTROINTESTINAL SURGERY. HOSPITAL GENERAL DE CASTELLÓN.

ABSTRACT

Bull horn lesions are frequent in the Latin world due to the existence of spectacles involving these animals. These wounds have special features that make them different from all other lesions. There is a special type of bull horn wound called sheathed goring. In this type of lesion, the skin returns to its normal appearance after the goring, but the injury is done. We report one patient with a sheathed goring and bowel evisceration that was only covered by the skin. The patient required emergency surgical intervention to repair the damaged bowel.

Key Words: *Sheathed goring. Bull horn wound. Abdominal trauma.*

INTRODUCTION

Injuries caused by bull charge are frequent in the Latin world, where shows with these animals are common practice. Patients that have been charged at by a bull, whether they have sustained injuries caused directly by the bull horns or not, must be managed as multiple trauma patients. Therefore, once we have ensured viability of the airway, control of the respiratory function and haemodynamic stability, we must pay attention to the possible associated injuries. On some occasions, these injuries may not be obvious in the initial assessment but can become devastating. They constitute a challenge for the physician's diagnostic skills. This is the case of sheathed goring, a subtype of gorings in which the bull horn,

Correspondence: David Martínez Ramos
Servicio de Cirugía General y Digestiva
Hospital General de Castellón
Avda. Benicassim, s/n
12004 Castellón
E-mail: davidmartinez@comcas.es

RESUMEN

**Cornada envainada.
Una lesión poco evidente pero devastadora**

Las heridas por asta de toro son una patología frecuente en el mundo latino, donde los espectáculos con este tipo de animales son algo habitual. Estas lesiones tienen unas características especiales que las diferencian de cualquier otro tipo de heridas. Existe un tipo especial de cornada que se conoce con el nombre de cornada envainada. En este tipo de cornada, la piel recupera su aspecto original, pero las lesiones por debajo de ella pueden ser extremadamente graves. Presentamos el caso de un paciente que sufrió una cornada envainada con evisceración intestinal en el que únicamente la piel cubría el contenido abdominal. Se requirió intervención quirúrgica urgente para la reparación abdominal.

Palabras clave: *Cornada envainada. Herida por asta de toro. Traumatismo abdominal.*

without breaking the patient's skin, perforates and contuses deeper tissues, muscles and aponeuroses causing eventration, evisceration and extremely severe lesions to viscera.

Insufficient knowledge about this type of goring can cause errors in diagnosis with disastrous consequences. Therefore, cases such as that presented here are useful for raising awareness of this type of injury.

CLINICAL CASE

The patient was a 42 year old male, with no significant medical history, that was brought to the Emergency Department after being gored by a bull during a bullfighting event.

Received: 5-10-2006
Accepted: 9-10-2007

On arrival, he had a blood pressure of 135/75 mmHg, a heart rate of 85 beats per minute, a respiratory rate of 20 breaths per minute and oxygen saturation of 97% measured by pulse oximetry.

In the physical exploration no neurological focality was found and the patient was conscious and oriented. Inspection showed multiple cutaneous erosions in the limbs and a small cutaneous erosion in the mesogastric area (Figure 1). The abdomen was soft, depressible and painless to palpation with no signs of peritonism. No masses or visceromegaly were found. Flexion movements and Valsalva manoeuvre rendered an evident bulging of the abdominal wall similar to that seen in patients with diastasis recti but that the patient had not noticed until that moment. We confirmed the presence of a reducible hernia and we found a hernia orifice with a maximum diameter of approximately 6 cm that was patent to palpation in the anterior abdominal wall.

With the diagnostic suspicion of eventration following a sheathed goring, an emergency computerised tomography (CT) scan was performed and showed perforation of the peritoneum and of the anterior muscle-aponeurotic abdominal wall through which small intestine loops emerged while the skin remained intact (Figure 2). The abdominal contents therefore remained separated solely by a thin skin layer. No other intra-abdominal injuries were found.

Contained evisceration caused by sheathed goring we diagnosed and emergency surgery was performed. During the operation the CT scan findings in the abdominal wall were confirmed – evisceration –, the abdominal organs were checked following the usual method and the damaged muscle

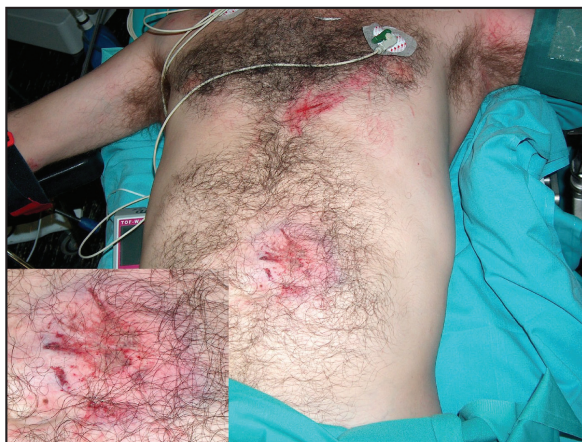

Figure 1. Image of the patient showing apparent integrity of the abdominal wall. In the box (lower left side), detail of the contused area with ecchymosis and erosion but without solution of continuity of the skin.

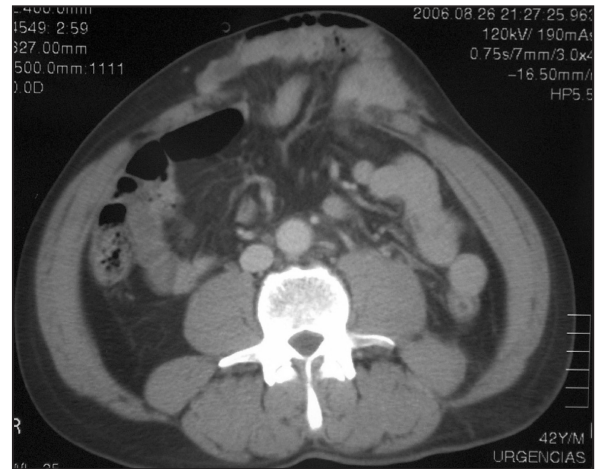


Figure 2. CT scan image showing a large orifice in the anterior abdominal wall through which small intestine loops emerge. A thin layer of skin contains the evisceration.

aponeuroses were closed with interrupted stitches using absorbable suture.

After carrying out a thorough lavage with normal saline and povidone-iodine solution, at all times over passive drains of the Penrose type, the skin was closed with silk sutures. There were no complications during the postoperative period.

DISCUSSION

Bull horn injuries are very frequent, especially in areas with a strong bullfighting tradition – professional or amateur – all over the world¹⁻⁶. In our environment, most of these injuries are found in young, single males during the summer months³⁻⁷. However, although they normally occur during bullfighting events, we must remember that these injuries can also be found in all those professionals that handle bulls in one way or another such as veterinary surgeons, transporters, live-stock farmers, slaughtermen, etc.

Wounds caused by bull horns present their own characteristics that make them different from any other type of injuries: presence of large tissue damage, different paths of injuries, cavities, twists and turns and culs-de-sac as well as massive inoculation of aerobic and anaerobic germs and the possibility of transmitting tetanus. Briefly, wounds by bull horns can be classified in four types: 1) sideways thrust (varetazo), where the horn thrusts the body tangentially causing only contusions; 2) jab (puntazo), where the injury is caused by the tip of the horn. They can be simple (puntazo simple), when the penetration of the horn is minimal and affects only superficial



levels, or extended (puntazo corrido), when the path of the wound is elongated; 3) misleading wound (herida despi-tante), where there is an orifice of entrance that is far from the core injury and where associated lesions can coexist; and 4) goring (cornada), which is a deep wound that affects fascia and muscle^{2,4,8}.

Among gorings, there is a subtype of special interest: sheathed gorings. This type of goring is also known as “goring on healthy” (cornada sobre sano) and it occurs when the bull horn penetrates the body but, due to the elastic capacity of the skin, there is no solution of continuity and the skin returns to its previous appearance or shows mild alteration (ecchymosis, haematoma, etc.)^{3,9-11}.

The importance of this type of goring lies in the fact that during inspection and even during palpation, it can be mistaken with a simple contusion. However, under a false appearance of mildness, injuries can be extremely severe and can require emergency surgery. This is the case of the contained eviscerations, like the one we present here, or of the perforations of hollow viscera as has been reported by other authors¹¹.

Therefore, when encountering a patient that apparently presents just contusions caused by bull horns, especially in the abdomen, we must carry out a thorough physical exploration using palpation to check systematically for possible aponeurosis damage or orifices in the abdominal wall. In this sense, Valsalva manoeuvre can be helpful for the assessment of possible eventrations. The presence of intense abdominal pain and/or peritonism during palpation must alert us of a possible intra-abdominal injury.

When suspecting an intra-abdominal injury – and if the clinical situation of patients allows it – it is recommended to

perform an ultrasound scan and/or an abdominal CT scan. The abdominal CT scan, besides diagnosing intra-abdominal lesions, enables the determination of the exact location and the size of the parietal damage as well as determining the contents of the eventration⁹.

In cases like the one described here, in which the peritoneum, the fascia and the muscles of the abdominal wall have been destroyed or perforated, the skin is the only structure that contains the evisceration and that separates the abdominal contents from the environment. Therefore, surgery must be an emergency priority. During the operation, it is advisable to check carefully every organ in the abdominal cavity and, after ruling out the presence of other associated injuries, the muscle-aponeurotic damage is repaired. Although a prosthesis or a mesh can be used in this repair if necessary, in the case we present here they were not used because the viability and strength of the muscle-aponeurotic tissue allowed primary closure.

As any wound caused by bull horns is considered to be soiled, regardless of the type of repair carried out, it is compulsory to carry out a debridement of the necrotic or devitalised tissues, to apply thorough lavage with normal saline and povidone-iodine, to use drains, to complete an antibiotic treatment with broad spectrum antibiotics and to administer the tetanus vaccine^{1,3}.

In conclusion, the integrity of the skin in a patient that has suffered a goring does not rule out a penetrating injury. Therefore, when encountering any injury caused by bull horn in the abdominal area, we must systematically assess the possibility of a sheathed goring even if the skin does not present obvious solution of continuity.

REFERENCES

- 1- Vázquez-Bayod R, Villanueva-Sáenz E, Gómez-García E. Aspectos generales en el manejo quirúrgico de las heridas por asta de toro en el Valle de México 1997-2000. Reporte de 42 casos. *Rev Mex Ortop Trauma* 2001;14:302-8.
- 2- Mansilla-Roselló A, Fuentes-Martos R, Astruc-Hoffmann A, Flores-Arcas A, Albert-Vila A, Fernández-Valdearenas R, et al. Estudio de 44 heridas por asta de toro. *Cir Esp* 1998;63:36-9.
- 3- Martínez-Ramos D, Miralles-Tena JM, Escrig-Sos J, Traver-Martínez G, Cisneros-Reig I, Salvador-Sanchís JL. Heridas por asta de toro en el Hospital General de Castellón. Estudio de 387 pacientes. *Cir Esp* 2006;80:16-22.
- 4- Hernández E, Gómez-Perlado B, Villaverde M, Vaquero G, Marugán JA, Besharat F, et al. Heridas por asta de toro. Estudio de 96 pacientes. *Cir Esp* 1996;59:156-9.
- 5- Ríos-Pacheco M, Pacheco-Guzmán R, Padrón-Arredondo G. Herida por asta de toro. Experiencia de un año en el Hospital General O’Horán. Mérida, Yucatán. *Cir Ciruj* 2003;71:55-60.
- 6- Zamora-Lomelí JA. Lesiones por embestida de toro de lidia en eventos civiles. Experiencia de 10 años. *Cirujano General* 2004;26:97-101.
- 7- Monferrer-Guardiola R. Heridas por asta de toro. Aspectos clínico-epidemiológicos de 204 casos asistidos en el Hospital General de Castelló, durante el periodo 1978-1988. *Ciencia Médica* 1990;7:262-71.
- 8- Navarro-Valle F, Bote-Mohedano JL, Duque-Cotrino S, Corcho-Gómez F, Martín-Domínguez C, Prado-Morales S. Herida penetrante en tórax por asta de toro. *Emergencias* 2003;15:243-6.
- 9- Zumárraga-Navas P, Sellés-Dechent R, Pardo-Correcher JM, Asencio-Arana D, Ruiz del Castillo J. Herida por asta de toro: cornada envainada. *Cir Esp* 1999;65:447-8.
- 10- Rebollo FJ, Bermejo A, López M, Utrillas A, del Val JM, González M, et al. Heridas por asta de toro y el “paseillo” del cirujano. *Cir Esp* 2001;69:525.
- 11- Salvoch JJ, Erce R, Otero A. Ahora lo sabemos, era una “cornada envainada”. *Cir Esp* 2002;71:51-3.